

## PENILE CIRCULAR FASCIOCUTANEOUS SKIN FLAP IN 1-STAGE RECONSTRUCTION OF COMPLEX ANTERIOR URETHRAL STRICTURES

JACK W. McANINCH\* AND ALLEN F. MOREY†

From the Department of Urology, University of California School of Medicine and San Francisco General Hospital, San Francisco, California

### ABSTRACT

**Purpose:** We review the applications and outcomes of penile circular fasciocutaneous flap urethroplasty in 66 patients at our institution.

**Materials and Methods:** We used a circular distal penile skin flap for urethral reconstruction in 66 men with complex urethral strictures. Average stricture length in this series was 9.08 cm. and mean followup was 41 months (range 1 to 7 years).

**Results:** The initial overall success rate was 79% (52 of 66 cases). Recurrent stenosis was noted in 7 of the 54 onlay (13%) and 7 of the 12 tubularized repairs (58%). Most recurrent strictures were successfully treated with a single subsequent procedure, including repeat urethroplasty in 5 cases and optical urethrotomy or dilation in 6. Two patients required perineal urethrostomy and 1 awaits further reconstruction. Including subsequent procedures, the overall long-term followup success rate was 95%. Neurovascular lower extremity complications developed in 4 patients after prolonged high lithotomy positioning.

**Conclusions:** Circular fasciocutaneous flap urethroplasty is a highly effective 1-stage method of reconstructing complex urethral strictures. Onlay repairs appear to be more successful than those involving flap tubularization. Limiting the time that the patient spends in the high lithotomy position appears to prevent neurovascular extremity complications.

**KEY WORDS:** urethra, penis, surgical flaps

The penile circular fasciocutaneous flap method of urethroplasty, which we first described in 1993,<sup>1,2</sup> has become the gold standard for reconstructing complex urethral strictures at our institution.<sup>3</sup> With this technique, a modification of a method described by Quartey,<sup>4</sup> a circumferential island of distal penile skin or foreskin is mobilized on a vascularized pedicle for urethral substitution. Because the distal penile skin is hairless, flexible and well vascularized, we have found that tissue from this area is versatile and reliable for urethral substitution. Full circumferential flap harvesting is possible in nearly all cases with excellent postoperative cosmetic results, even in previously circumcised men. We review the applications and outcomes of circular fasciocutaneous flap urethroplasty in 66 patients at our institution.

### PATIENTS AND METHODS

From 1990 to 1997 more than 300 men underwent urethroplasty at our institution, including 66 with complex urethral strictures who underwent reconstruction via the penile circular fasciocutaneous flap technique. In most patients long strictures involved the pendulous and/or bulbar urethra (fig. 1). Men with isolated strictures of the fossa navicularis were excluded from study.

Average stricture length in this series was 9.08 cm. (range 4 to 24). In 25 patients strictures were 10 cm. or longer. In 54 patients onlay procedures were performed, while 12 others underwent flap tubularization for urethral substitution. Adjunctive tissue transfer was done in 18 patients, including a proximal graft for a panurethral stricture in 9 and excision with primary anastomosis for a focally dense stricture in 9. In

all cases followup was more than 1 year (range 1 to 7, mean 41 months).

**Surgical anatomy of the penile flap.** A clear understanding of penile anatomy and the relationship of the penile fasciae is essential for the surgical development of the penile flap. Figure 2 shows the anatomy of the fasciae, soft tissues and vasculature of the distal penile flap. The thin membranous layer of subdermal tissue (dartos fascia) that lies beneath the skin is reflected with the penile skin to preserve the delicate subdermal skin blood supply. The tunica dartos, which is homologous to the tunica dartos of the scrotum, comprises the flap pedicle. It is composed of abundant smooth muscle fibers, connective tissue, elastic fibers and blood vessels. The tunica dartos has a robust blood supply based on the terminal arborization of the superficial external pudendal arteries, and its venous drainage exists through the superficial dorsal penile veins.<sup>4</sup>

Buck's fascia is a well defined fascia adjacent to the tunica albuginea of the penis, and acts as the supporting layer for the tunica dartos flap pedicle.<sup>5,6</sup> The penile nerves, deep dorsal veins and arteries lie deep to Buck's fascia and remain intact in their normal position as the flap is developed. It should be noted that Buck's fascia separates into superficial and deep lamellae that diverge to envelop the deep penile neurovascular structures dorsally and the corpus spongiosum ventrally. Only the superficial lamella of Buck's fascia is elevated with the pedicle over the dorsal neurovascular bundle and the urethra. The island of skin, also called an island flap, is used as a replacement or onlay in urethral reconstruction. The term fasciocutaneous flap refers to the use of Buck's fascia as the primary supporting fascia of the tunica dartos vascular pedicle as it passes to the island of penile skin.

**Harvesting the flap.** Patients with distal strictures are placed in the low lithotomy or supine position throughout the procedure. Those requiring more proximal reconstruction are placed in the high lithotomy position. A 2-zero silk suture is

Accepted for publication October 23, 1997.

\* Requests for reprints: Urology 3A20, San Francisco General Hospital, 1001 Potrero Ave., San Francisco, California 94110.

† Current address: Brooke Army Medical Center, MCHE-SDU, Building 3600, Room 225-5, 3851 Roger Brooke Dr., Fort Sam Houston, Texas 78234-6360.

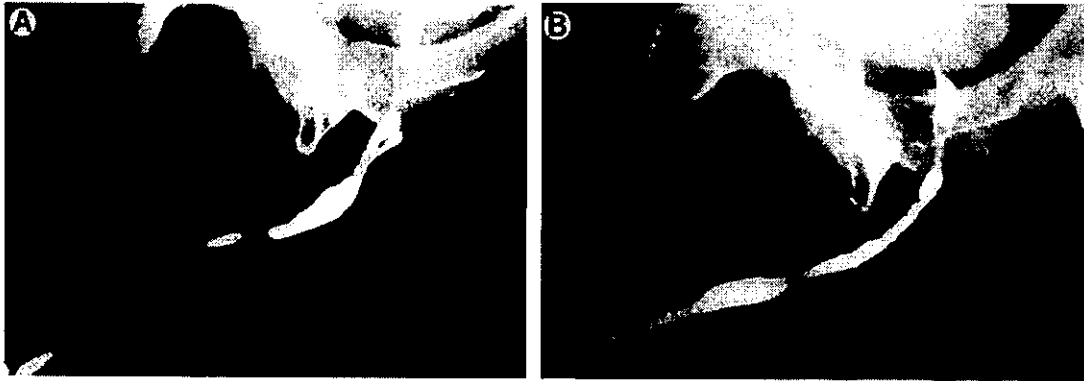


FIG. 1. Retrograde urethrography. A, long distal stricture is ideally suited for circular fasciocutaneous flap urethroplasty. B, postoperatively urethra is widely patent after 14 cm. circular fasciocutaneous flap onlay reconstruction.

placed in the glans just above the urethral meatus to provide stretch and control for graft harvesting. The circular flap is obtained from the distal penile skin or foreskin to ensure hairlessness. A fine circumferential line of brilliant green dye is drawn approximately 5 mm. proximal to the corona. Flap width varies according to the amount of tissue needed to produce a final urethral lumen of approximately 26F. The usual width for onlay cases is 17 to 20 mm. When tubularization is necessary, 25 mm. are obtained.

Superficial proximal circumferential dissection is begun by incising the thin dartos fascia superficial to the thick tunica dartos pedicle. The dartos fascia is elevated with the penile skin along the shaft of the penis, protecting the subdermal vascular plexus and, thereby, preventing skin necrosis. Deep distal circumferential dissection is begun beneath Buck's fascia on the lateral aspect of the penis, avoiding the urethra and the dorsal neurovascular structures. The dorsal penile neurovascular complex and tunica albuginea are exposed and preserved, since the superficial lamella of Buck's fascia is elevated with the flap. This dissection is carried to the base of the penis. Care is taken to ensure adequate hemostasis with bipolar cautery.

The flap is split in the mid ventral plane and stay sutures are placed at each end. Thus, the circular configuration becomes a longitudinal strip of skin, which is then rotated to 1 side for transfer to the area of repair (fig. 3). The typical length of the flap is 12 to 15 cm.

*Stricture exposure and anastomosis.* A 20F catheter is

passed until it is palpated at the distal extent of the stricture. For distal strictures the previous circumferential incision provides adequate urethral exposure. For more proximal strictures a midline perineal incision is also required. Strictures extending under the scrotum can usually be accessed via either or both of these approaches without dividing the scrotum. The urethra and spongiosum are incised along the entire length of the stricture until a 28F bougie passes easily into the bladder. The distal end of the stricture is opened until it easily accepts a 26F bougie.

In proximal repair the flap is passed through a scrotal tunnel to the bulb. It is important to avoid twisting or placing excessive tension on the flap. A running, continuous, watertight urethral anastomosis is created with 5 or 6-zero monofilament polyglyconate along each flap edge. A 16F silicone Foley catheter is placed. Suprapubic urinary diversion is usually not done. As the second suture line nears completion, the flap is tailored near the distal apex and the suture is tied. Redundant skin is carefully excised from the remainder of the flap, preserving the underlying pedicle. Skin closure is performed with interrupted fine chromic suture. Circumferential compression bandages are avoided postoperatively.

Most patients are discharged from the hospital on day 2 postoperatively. The urethral catheter remains in place for 3 weeks. Retrograde urethrography and flow rate measurement are performed 3 months and 1 year postoperatively.

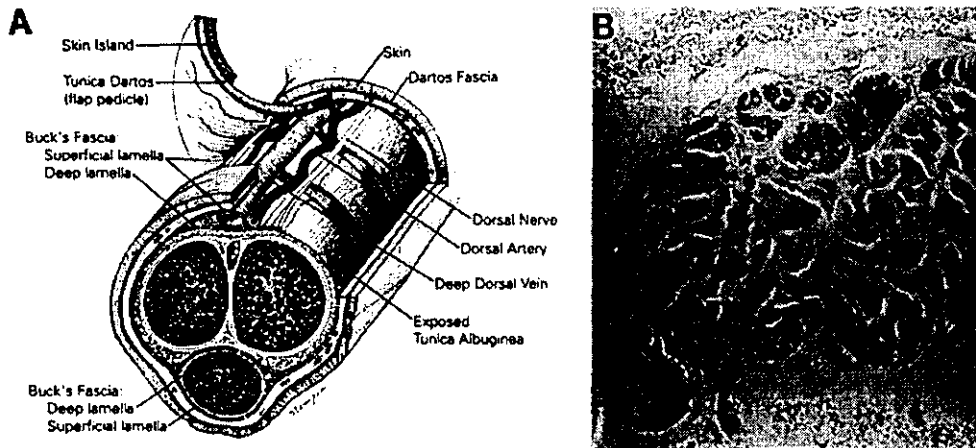


FIG. 2. Anatomy of circular penile fasciocutaneous flap. A, flap pedicle is supplied by terminal branches of superficial external pudendal arteries within tunica dartos. B, strongly positive actin stain reveals abundant smooth muscle bundles within tunica dartos flap. Reduced from  $\times 400$ .

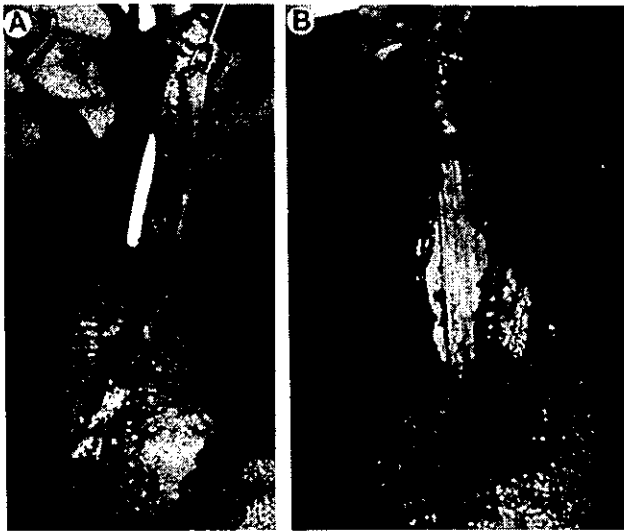


FIG. 3. Technique of circular fasciocutaneous flap urethroplasty. A, circular pedicle is split ventrally and flap is rotated to 1 side, providing up to 15 cm. of vascularized tissue for urethral substitution. B, ipsilateral back wall anastomosis is completed first.

#### RESULTS

In our experience the overall initial success rate of circular fasciocutaneous flap urethroplasty was 79%. After an additional procedure the long-term followup success rate was 95%. After the initial procedure recurrent stricture was noted in 14 patients (21%), usually at the proximal or distal anastomosis. Repeat urethroplasty elected for recurrent strictures 1 to 2.5 cm. long was successful in 5 of 7 cases. A single direct vision internal urethrotomy or dilation performed for shorter stricture recurrence was successful in 6 of 7 cases. Two patients each required perineal urethrostomy and fistula closure. Only 1 patient has needed more than 1 additional surgical procedure and none has required repeat dilation or self-catheterization.

The penile circular fasciocutaneous flap reliably provided 12 to 15 cm. of length for reconstruction in most patients, although approximately 90% had previously been circumcised. Seven of the 12 men (58%) who underwent flap tubularization for urethral replacement required a repeat procedure for recurrent stenosis, including end-to-end urethroplasty in 3, direct vision internal urethrotomy in 3 and dilation in 1. One patient with an 11 cm. tubularized flap who had recurrent stenosis at the proximal anastomosis after repeat urethroplasty and direct vision internal urethrotomy awaits further treatment.

For onlay repair the initial success rate was 87% (47 of 54 cases) and the long-term success rate was 98% (53 of 54) after an additional procedure. The table shows associated complications. A 78-year-old man died suddenly 2 weeks postoperatively of precipitous respiratory failure.

#### DISCUSSION

A major advantage of the circular fasciocutaneous penile skin flap is its versatility, since it can be used in all areas of the urethra from the membranous area to the meatus (fig. 4). The circular fasciocutaneous flap is easily combined with other tissue transfer techniques when necessary, enabling 1-stage reconstruction in the majority of cases.<sup>7</sup> The flap may also be partially tubularized or divided between 2 disparate stenotic areas. The circular fasciocutaneous flap technique provides superior results in patients with complex refractory strictures in whom previous anterior urethroplasty has failed.<sup>8</sup> We believe that the circular fasciocutaneous flap is

Complications of penile circular fasciocutaneous skin flap urethroplasty in 66 patients

Complication	No. Pts. (%)
Recurrent stricture, successful reoperation	4 (6)
Recurrent stricture, single dilation or direct vision internal urethrotomy	7 (11)
Recurrent stricture, perineal urethrostomy	2 (3)
Recurrent stricture, awaiting further reconstruction	1 (2)
Transient extravasation	3 (4)
Fistula	2 (3)
Compartmental syndrome (fasciotomy)	2 (3)
Transient leg neuropathy	2 (3)
Penile skin slough	3 (4)
Pseudodiverticulum	1 (2)
Hematoma	1 (2)
Postop. myocardial infarction	1 (2)
Postop. death	1 (2)

superior because it brings well vascularized tissue to the compromised area. Redundant or hair-bearing urethral tissues from previous repairs may be completely excised because the circular fasciocutaneous flap provides abundant tissue that is ideally suited for urethral substitution.

Most cases in which flap tubularization was performed for urethral replacement were treated early in this series. We now prefer to maintain the urethral plate, using the flap as an onlay reconstruction whenever possible. In most cases now requiring flap tubularization urethral continuity was lost as the result of trauma (fig. 5).

In our experience a devastating complication was compartmental syndrome of the lower extremities, which was noted only in 2 complex cases with prolonged high lithotomy positioning (7 and 10 hours, respectively). It is difficult to predict the patients at risk for this complication but the risk is likely increased when the patient remains for more than 5 hours in the high lithotomy position.<sup>9-11</sup> Because average operative time in this series was approximately 6 hours, the compartmental syndrome must always be considered a potential complication of circular fasciocutaneous flap urethroplasty. To prevent leg complications we now begin all cases with flap harvesting while the patient is initially supine. Thus, time spent in the lithotomy position is decreased by 2 to 3 hours. The penis is covered with nonadhesive gauze under a sterile adhesive film during high lithotomy repositioning. The adhesive and gauze are removed during sterile preparation of the perineum. Beginning the repair with flap harvesting has proved successful in preventing complications and it also decreases urethral blood loss.

Necrosis of the penile skin proximal to the flap results when the vascular supply of the subdermal plexus is compromised. Although 3 patients had significant penile skin necrosis, all healed successfully by secondary intent and none required grafting. To prevent skin slough it is helpful at the onset of proximal circumferential dissection to lift and divide the delicate dartos fascia between 2 jeweller forceps. By dissecting beneath the dartos fascia the overlying subdermal plexus is protected and skin viability is ensured. Uncircumcised patients should be circumcised after flap harvesting to eliminate unneeded skin that may be at risk for ischemic injury. Redundant prepuce is of limited value from a reconstructive standpoint after circular fasciocutaneous flap urethroplasty because further penile flap procedures would be imprudent. Moreover, buccal mucosa is readily available in all cases should subsequent substitution urethroplasty be indicated.

To prevent pseudodiverticulum formation we rarely develop penile skin flaps more than 20 mm. wide when performing onlay reconstruction. The combined flap plus urethral plate circumference targeted is approximately 26F in adults. When the urethral plate is preserved, a smooth contour is usually shown on postoperative radiography with a flap 18 to 20 mm wide. Penile tethering is avoided by freeing

## PENILE CIRCULAR FASCIOCUTANEOUS SKIN FLAP

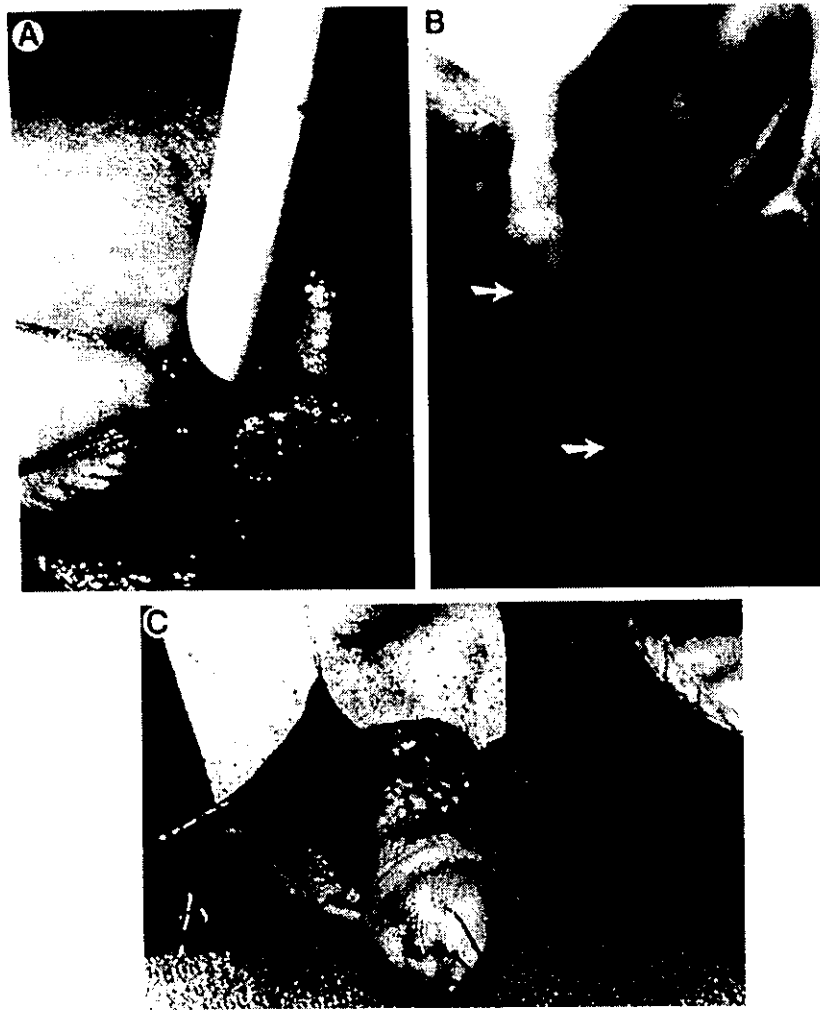

FIG. 4. All areas of urethra are accessible for reconstruction. *A*, flap is easily advanced to urethral meatus, when indicated. *B*, postoperative voiding cystourethrogram shows 8 cm. circular fasciocutaneous flap onlay reconstruction up to bladder neck (arrows) in man with extensive posterior urethral stricture after radical perineal prostatectomy and pelvic radiotherapy. *C*, flap may be split dorsally and applied to noncontiguous strictures.

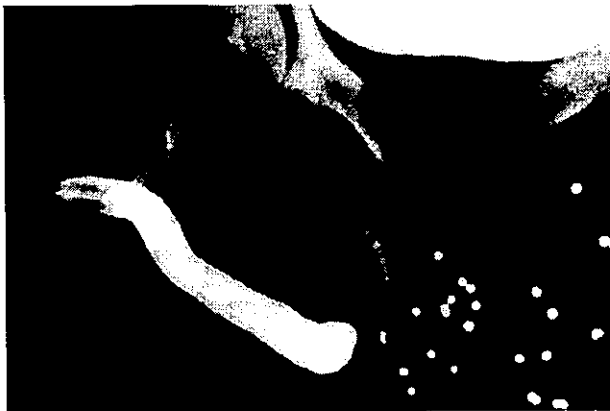


FIG. 5. In patient who received shotgun blast to perineum at close range preoperative retrograde urethrography reveals long urethral defect requiring complete proximal urethral replacement by flap tubularization.

the flap adequately off of the proximal shaft until no tension exists. To prevent anesthesia in the glans and distal foreskin, injury to the dorsal neurovascular bundles must be avoided

when dissecting the dorsal lamella of Buck's fascia off of these structures. Hematoma, which may result from the open corpus spongiosum on either side of the urethral anastomosis, may be prevented by closing the spongiosum with a running absorbable suture. A perineal Jackson-Pratt drain is often helpful.

Stricture recurrence is a troublesome complication in 21% of our patients after the initial procedure. Recurrence is usually focal and located at the proximal or distal anastomotic margin. It is usually resolved by a single subsequent optical urethrotomy or resection with end-to-end anastomosis. Many recurrences seem to develop within the scrotal portion of the urethra, and so it is critical to emphasize adequate exposure and accurate suture placement in this area. It is important to include in the original operative note the side to which the flap was rotated so that, if reoperation becomes necessary, dissection may be performed favoring the contralateral side. When failure occurs, it is noted within several months postoperatively. Delayed failure has not been observed.

Circular fasciocutaneous flap urethroplasty is a lengthy, rigorous procedure that should be reserved for long or complex strictures. Discrete bulbar strictures 2.5 cm. long or less are best treated with resection and end-to-end anastomosis. Buccal mucosa grafts have proved reliable for many interme-

diate 2.5 to 6 cm. bulbar strictures.<sup>12</sup> Circular fasciocutaneous flap urethroplasty is ideal for long strictures in the distal urethra, where the decreased substance of the corpus spongiosum may jeopardize graft viability but is readily applicable for bulbar reconstruction. Patients must generally be in good health and they must undergo careful preoperative evaluation of associated medical problems. Preoperative sonourethrography allows accurate stricture measurement, which has proved valuable for guiding procedure selection.<sup>13</sup>

#### CONCLUSIONS

The penile circular fasciocutaneous flap provides ample tissue for urethral substitution and it may be reliably used in nearly all complex adult strictures. Its versatility and effectiveness are noteworthy. We believe that 1-stage reconstruction using the circular fasciocutaneous flap technique is superior to 2-stage procedures, such as those involving split-thickness skin grafts, and it avoids the problems of hair-bearing flaps. Revision urethroplasty has proved highly effective for stricture recurrence. Onlay reconstruction is preferable to flap tubularization whenever possible. The most troublesome complication of circular fasciocutaneous flap urethroplasty is neurovascular injury to the lower extremities, which occurs secondary to prolonged high lithotomy positioning. This type of complication may be prevented by beginning the procedure with the patient supine for flap harvesting, and then repositioning him for flap transfer and anastomosis.

#### REFERENCES

1. McAninch, J. W.: Reconstruction of extensive urethral strictures: circular fasciocutaneous penile flap. *J. Urol.*, **149**: 488, 1993.
2. Morey, A. F. and McAninch, J. W.: Penile circular fasciocutaneous flap urethroplasty. *Atlas Urol. Clin. N. Amer.*, **5**: 45, 1997.
3. McAninch, J. W.: Fasciocutaneous penile flap urethroplasty in reconstruction of complex anterior urethral strictures. In: *Traumatic and Reconstructive Urology*. Philadelphia: W. B. Saunders Co., chapt. 51, pp. 609-613, 1996.
4. Quartey, J. K.: One-stage penile/preputial island flap urethroplasty for urethral stricture. *J. Urol.*, **134**: 474, 1985.
5. Buck, G., Jr.: A new feature in the anatomical structure of the genito-urinary organs not hitherto described. *Trans. Amer. Med. Ass.*, **1**: 367, 1848.
6. Markee, J. E.: The urogenital system. In: *Morris' Human Anatomy*, 11th ed. Edited by J. P. Schaeffer. New York: McGraw-Hill, p. 1530, 1953.
7. Wessells, H., Morey, A. F. and McAninch, J. W.: Single stage reconstruction of complex anterior urethral strictures: combined tissue transfer techniques. *J. Urol.*, **157**: 1271, 1997.
8. Morey, A. F., Duckett, C. P. and McAninch, J. W.: Failed anterior urethroplasty: guidelines for reconstruction. *J. Urol.*, **158**: 1383, 1997.
9. Moses, T. A., Kreder, K. J. and Thrasher, J. B.: Compartment syndrome: an unusual complication of the lithotomy position. *Urology*, **43**: 746, 1994.
10. Peters, P., Baker, S. R., Leopold, P. W., Taub, N. A. and Burnand, K. G.: Compartment syndrome following prolonged pelvic surgery. *Brit. J. Surg.*, **81**: 1128, 1994.
11. Angermeier, K. W. and Jordan, G. H.: Complications of the exaggerated lithotomy position: a review of 177 cases. *J. Urol.*, **151**: 866, 1994.
12. Morey, A. F. and McAninch, J. W.: When and how to use buccal mucosa grafts in adult bulbar urethroplasty. *Urology*, **48**: 194, 1996.
13. Morey, A. F. and McAninch, J. W.: Role of preoperative sonourethrography in bulbar urethral reconstruction. *J. Urol.*, **158**: 1376, 1997.