

available at [www.sciencedirect.com](http://www.sciencedirect.com)  
journal homepage: [www.europeanurology.com](http://www.europeanurology.com)



## Surgery in Motion

# Combined Dorsal plus Ventral Double Buccal Mucosa Graft in Bulbar Urethral Reconstruction

Enzo Palminteri<sup>a,\*</sup>, Gianantonio Manzoni<sup>b</sup>, Elisa Berdondini<sup>a</sup>, Francesco Di Fiore<sup>c</sup>, Gianfranco Testa<sup>c</sup>, Maurizio Poluzzi<sup>d</sup>, Angelo Molon<sup>d</sup>

<sup>a</sup> Center for Urethral and Genitalia Reconstructive Surgery, Arezzo, Italy

<sup>b</sup> Sezione Urologia Pediatrica, Divisione di Urologia, Ospedale Circolo, Varese, Italy

<sup>c</sup> U.O. Urologia, Ospedale Monaldi, Napoli, Italy

<sup>d</sup> Dipartimento di Urologia, Ospedale Sacro Cuore, Negrar, Italy

### Article info

#### Article history:

Accepted May 31, 2007

Published online ahead of  
print on June 8, 2007

#### Keywords:

Buccal mucosa  
Graft  
Urethra  
Urethral stricture

### Abstract

**Objectives:** We describe a technique for bulbar urethral reconstruction using a combined dorsal plus ventral double buccal mucosa graft (BMG). **Methods:** From March 2002 to June 2006, 48 men, mean age 35 yr, with bulbar strictures underwent patch urethroplasty using a dorsal plus a ventral double BMG. Average stricture length was 3.65 cm (range: 2–10 cm). The stenotic urethral segment was opened along its ventral surface; the exposed dorsal urethra was incised in the midline to create an elliptical area over the tunica albuginea where the dorsal inlay BMG was placed and quilted to the corpora to augment dorsally the urethral plate. Subsequently, the ventral onlay BMG was sutured to the urethral lateral margins to complete the augmented urethroplasty. Finally, the spongiosum was closed over the graft. Successful reconstruction was defined as normal voiding without the need for any postoperative procedure including dilation.

**Results:** Mean follow-up was 22 mo (range: 13–59 mo). At the catheter removal 3 wk after surgery, in three patients the voiding cystourethrography showed a fistula, which recovered after a prolonged catheterization. Of 48 cases, 43 (89.6%) were successful and 5 (10.4%) failures with recurrence of the stricture; 4 were treated with internal urethrotomy and 1 with a temporary perineal urethrostomy.

**Conclusions:** Preliminary results with a combined double BMG urethroplasty for severe bulbar stricture are encouraging. The double dorsal and ventral graft may provide a simple and reliable solution to achieve an adequate urethral lumen in selected patients.

© 2007 European Association of Urology. Published by Elsevier B.V. All rights reserved.

\* Corresponding author. Centre of Urethral and Genital Reconstruction, Via Fra' Guittone 2, 52100 Arezzo, Italy. Tel. +39 335 7012783; Fax: +39 0575 27056.  
E-mail address: [enzo.palminteri@inwind.it](mailto:enzo.palminteri@inwind.it) (E. Palminteri).

## 1. Introduction

Several surgical techniques have been described to treat bulbar urethral strictures based on stricture length. Bulbar strictures <2 cm are generally repaired with excision and end-to-end anastomosis; for strictures 2–3 cm in length a graft-augmented anastomotic procedure has been advocated, whereas strictures >3 cm are usually repaired by patch urethroplasty using a buccal mucosa graft (BMG) [1–4].

The advantages of the BMG, compared to penile skin flaps or other kind of grafts such as genital/extragenital skin or bladder/intestinal mucosae, include a cosmetically superior incision, decreased operative time, low harvest morbidity, and better histologic characteristics of the graft [3,5].

The techniques are various and the location of the patch has become a contentious issue with different series reporting BMGs placed either ventrally or dorsally to augment the strictured urethra [6–10].

We report our medium-term follow-up in bulbar urethral reconstruction using a combined dorsal inlay plus a ventral onlay double BMG to augment the preserved urethral plate.

## 2. Methods

Between March 2002 and June 2006 we repaired 48 bulbar urethral strictures with a double BMG. Mean patient age was 35 yr (range: 8–69 yr). Stricture etiology was unknown in 34 cases, ischemia in 10, trauma in 3, and urethritis in 1. Forty-seven patients (98%) had undergone an average of 2.5 prior urethrotomies (range: 1–9) and dilatations.

### 2.1. Preoperative evaluation

Preoperative evaluation included clinical history, physical examination, urine culture, uroflowmetry, retrograde voiding cystourethrography, sonourethrography, and urethroscopy. Sonourethrography was performed at the same time as the retrograde cystourethrography, reducing the discomfort of an additional investigation. Patients were informed that bulbar patch urethroplasty is a safe procedure as far as sexual function is concerned.

### 2.2. Surgical technique

We performed the bulbar urethroplasty using a dorsal inlay plus ventral onlay double graft of buccal mucosa for the urethral augmentation.

The urethral procedure is done with the patient in the normal lithotomy position. Through a Y-inverted incision the bulbocavernous muscles are divided, exposing the bulbar urethra. Using a ventral-sagittal urethrotomy the strictured urethra is opened, guided by a guidewire, and methylene blue previously injected to define the narrow lumen. The urethra is

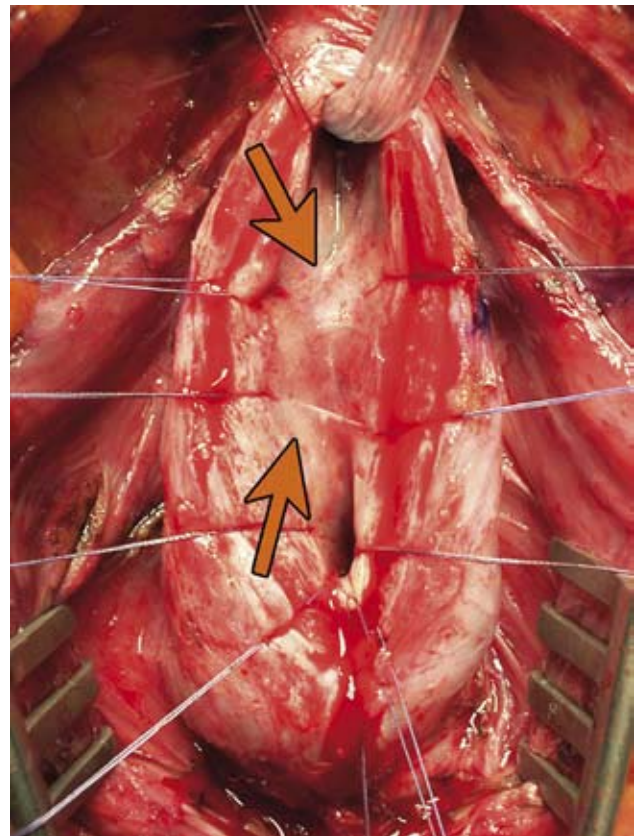


Fig. 1 – Urethral plate with stenotic rings (arrows).

laid open for 1 cm both proximally and distally into the healthy urethra (Fig. 1).

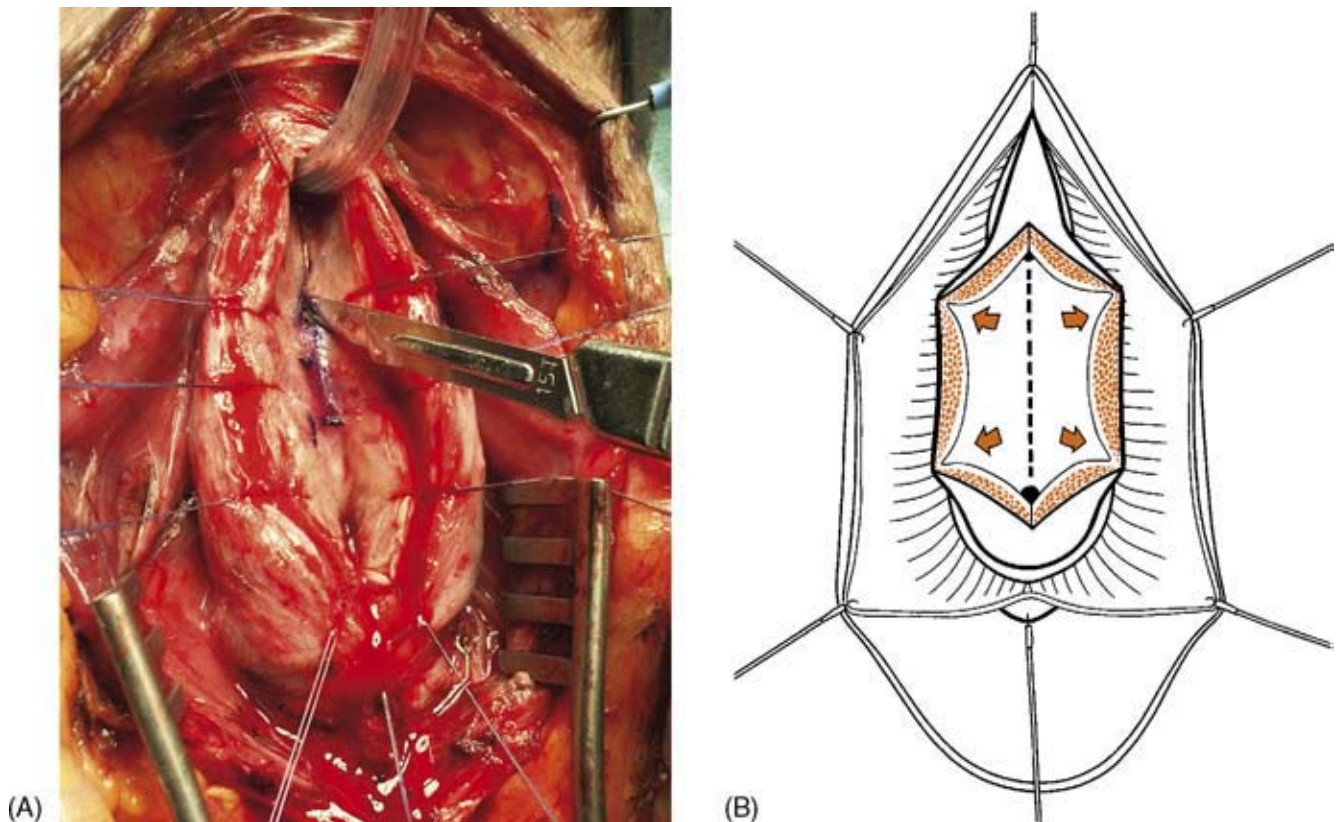
#### 2.2.1. Dorsal inlay patch augmentation

As Asopa suggested, the exposed dorsal urethra is incised in the midline down to the tunica albuginea [11]. The margins of the incised dorsal urethra are dissected from the tunica by sharp dissection with a scalpel, without lifting the two halves of the bisected urethra (Fig. 2); an elliptical raw area is created over the tunica albuginea (Fig. 3) and the incised dorsal free margins of the urethra are anchored by interrupted sutures to the tunica. The first BMG is sutured into the recipient elliptical area; the graft is quilted to the underlying tunica and fixed to the urethral mucosal margins with interrupted sutures of 6-0 polyglactin to prevent the formation of a potential hematoma into a dead space (Fig. 4).

#### 2.2.2. Ventral onlay patch augmentation

Subsequently to the dorsal urethral augmentation, the lumen is also graft-enlarged ventrally according to the McAninch procedure; the second BMG is sutured laterally to the left mucosal margin of the urethral plate with a 6-0 running suture [3]. The catheter is inserted and finally the graft is rotated and sutured laterally to the right mucosal margin (Fig. 5).

An inverted ventral graft quilting is made with few stitches fixing the spongiosum to the graft. Finally the adventitia of the spongiosum is closed over the graft with a 4-0 running suture (Fig. 6).



**Fig. 2 – (A) Dorsal incision to release the stenotic rings. (B) The margins of the incised dorsal urethra are dissected from the tunica without lifting the two halves of the bisected urethra.**

The preoperative assessment by urethrography and ultrasonography (Fig. 7) may help in selecting the procedure, but in urethral reconstruction usually intraoperative local factors will indicate the final choice of the technique. Thus, we used the combined double patch to enlarge the urethra better in tight strictures characterized by a narrow residual urethral plate, scarred or compromised from stenotic rings, in which a single patch seemed to be insufficient to make a wide enough lumen.

In all patients after the combined ventral and dorsal opening of the stricture, the fibrotic tissue is partially excised from the urethral margins while preserving the remaining urethral plate. Neo-urethras were created by anastomosing the BMGs in inlay/onlay patch fashion to the mucosal margins of the urethral plate.

We used a two-team approach, with one team harvesting the BMG and the second team exposing the stricture. The BMG was harvested from the inner cheek and the donor site closed with 4-0 polyglactin interrupted stitches or running suture. We initially used a nasotracheal intubation but we noticed that this resulted in more postoperative discomfort and no greater access to the inner cheek. Now we prefer an orotracheal tube taped over to the contralateral side and a Kilner-Doughty oral retractor, which provides excellent exposure of the inner cheek (Fig. 8).

In 5 patients the two BMGs were harvested bilaterally from both cheeks, and in the other 43 patients a wide single BMG

was harvested from the right cheek and subsequently tailored into two smaller grafts according to the length of the dorsal and ventral urethral openings.

The average length of the harvested graft was 6.16 cm (range: 4–8 cm) and average width of the harvested graft, 1.89 cm (range: 1–2.5 cm). The average length of the graft used dorsally was 2.36 cm (range: 1–5 cm) and that of the graft used ventrally was 4.68 cm (range: 4–11 cm). Average stricture length was 3.65 cm (range: 2–10 cm).

A 16F silicone Foley catheter was left in place. Patients were discharged home on the third postoperative day. Voiding cystourethrography was done at catheter removal 3 wks after surgery. Uroflowmetry and urine cultures were repeated every 4 mo during the first year and annually thereafter. Whenever obstructive symptoms developed or peak flow rate deteriorated to <14 ml/s, urethrography and urethroscopy were repeated. Successful reconstruction was defined as normal voiding without need for any postoperative procedure, including dilation.

### 3. Results

Mean follow up was 22 mo (range: 13–59 mo). Of 48 cases, 43 (89.6%) were successful and 5 (10.4%) were failures. There were no early postoperative complications, such as wound infections, hematomas, or

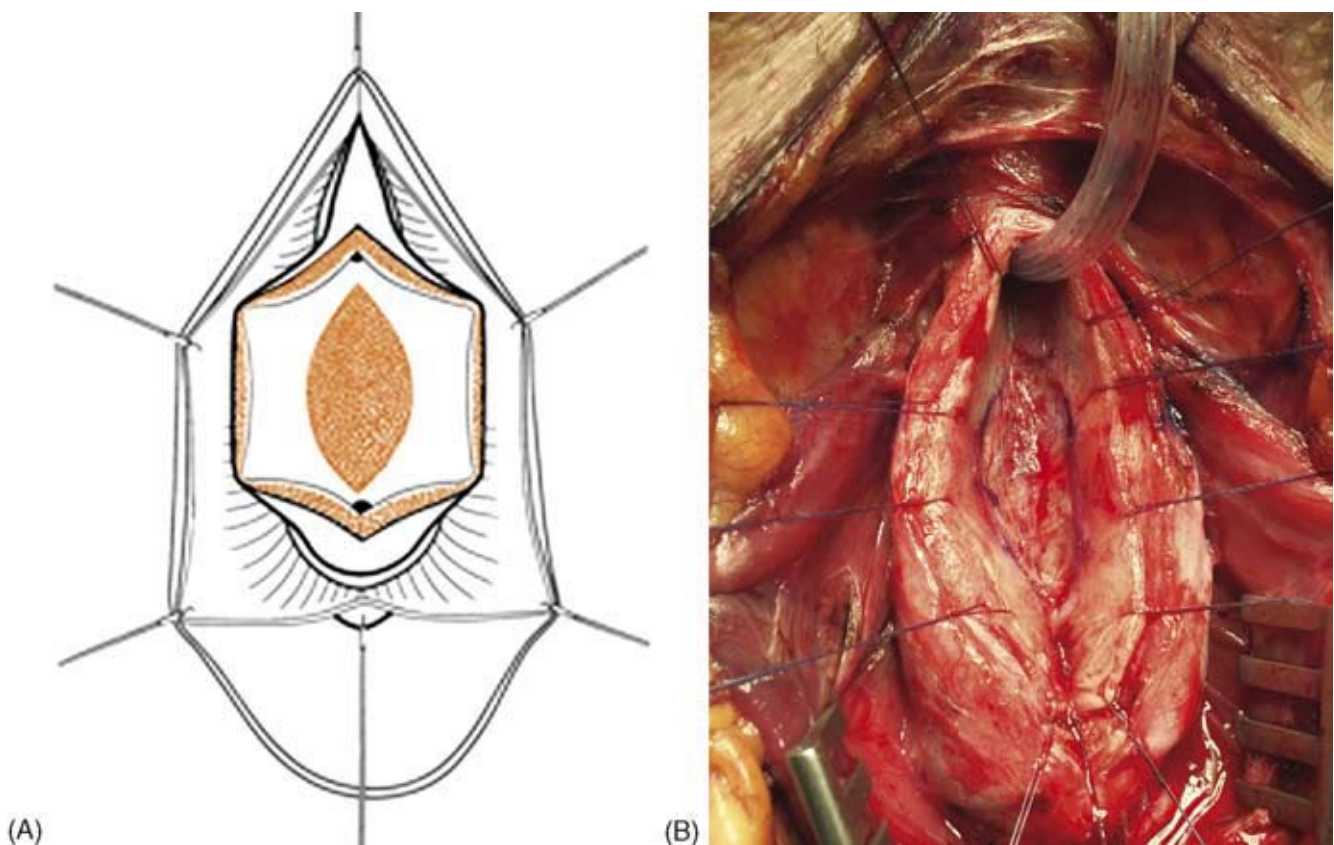


Fig. 3 - (A-B) An elliptical raw area is created over the tunica albuginea.

bleeding. In three patients a fistula was evident at the voiding urethrography after catheter removal; a 12F Foley catheter was reinserted and maintained for two additional weeks with subsequent fistula resolution.

Postoperative average peak urinary flow of successful patients was 31.02 ml/s versus the preoperative average peak urinary flow of 7.64 ml/s. Of the successful cases, average stricture length was 3.53 cm, average dorsal graft length 2.32 cm, and average ventral graft length 4.47 cm. Of the five patients in whom treatment failed, average stricture length was 4.4 cm, average dorsal graft length 3.1 cm, and average ventral graft length 5.6 cm.

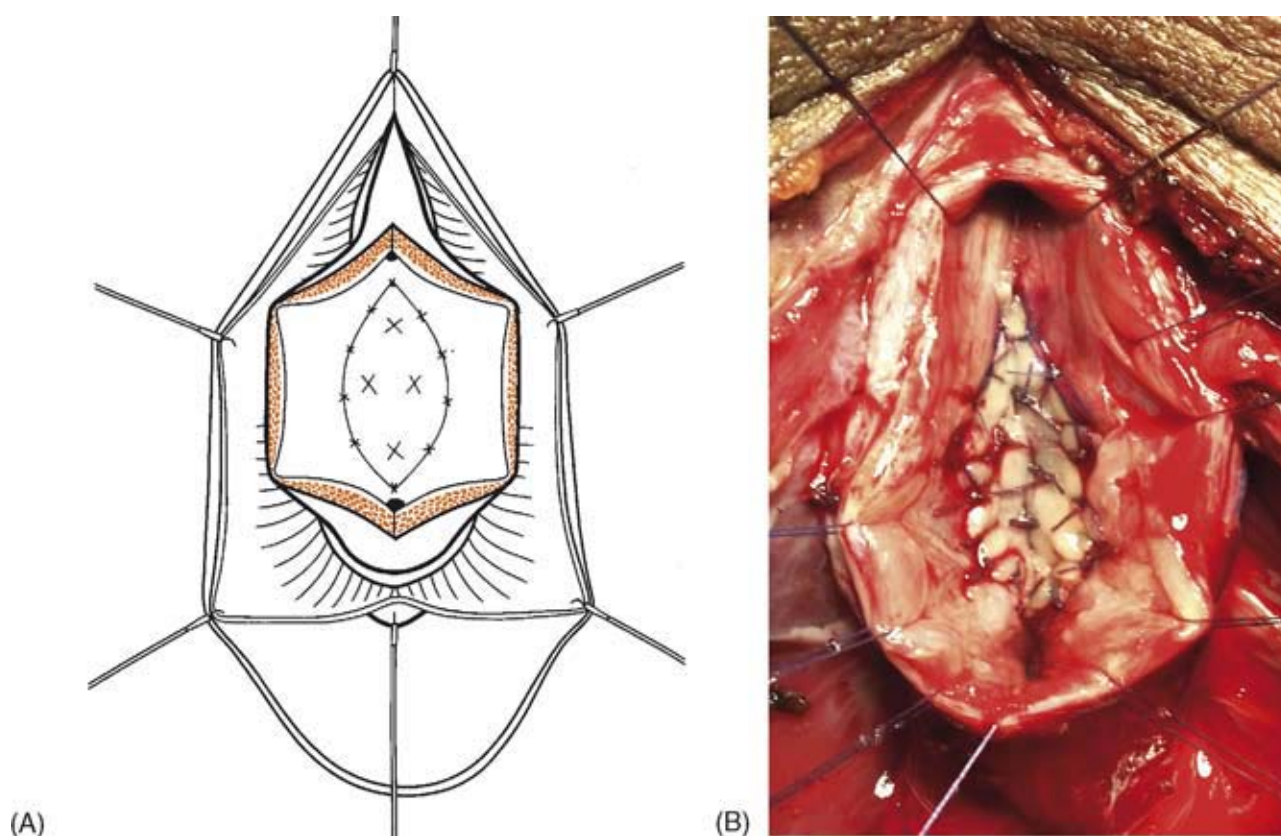
In all patients with stricture recurrence the radiologic and endoscopic evaluation provided useful information about disease extension. Of the five failures, two patients developed a resticture 1 cm long at the distal site of the urethral reconstruction, one patient developed a stenotic ring at the distal site of the urethral reconstruction, and one patient had two stenotic rings together at the distal and proximal site of the urethral reconstruction. All these patients were treated with internal urethrotomy. One failure occurred in a patient, aged 8 yr,

with a primary ischemic stricture 10 cm long who underwent to dorsal augmentation by a BMG 4 cm long and ventral augmentation by two BMGs placed serially (5 cm plus 5 cm). This child developed two restrictures, both 1 cm long; the fibrotic urethral tract was opened leaving a perineal urethrostomy and currently the patient is awaiting a staged solution. Primary stricture etiology of the failures was ischemic in one case and unknown in four. Recurrences developed within 6 mo after surgery in three cases and within 12 mo in two.

Of 48 patients, 3 (6%) referred semen sequestration but urethrography and urethroscopy failed to demonstrate urethrocele.

#### 4. Discussion

Anastomotic urethroplasty has traditionally been reserved for strictures no more than 2 cm long, but recently the accepted limits are expanding and successful anastomotic repair was reported for urethral defects of 3 or, even up to 5 cm [1,12]. However, in addition to the resected strictured tract, the need of spatulation of the two stumps may



**Fig. 4 – Dorsal inlay patch augmentation. (A and B) the first buccal mucosa graft is sutured and quilted into the recipient elliptical area.**

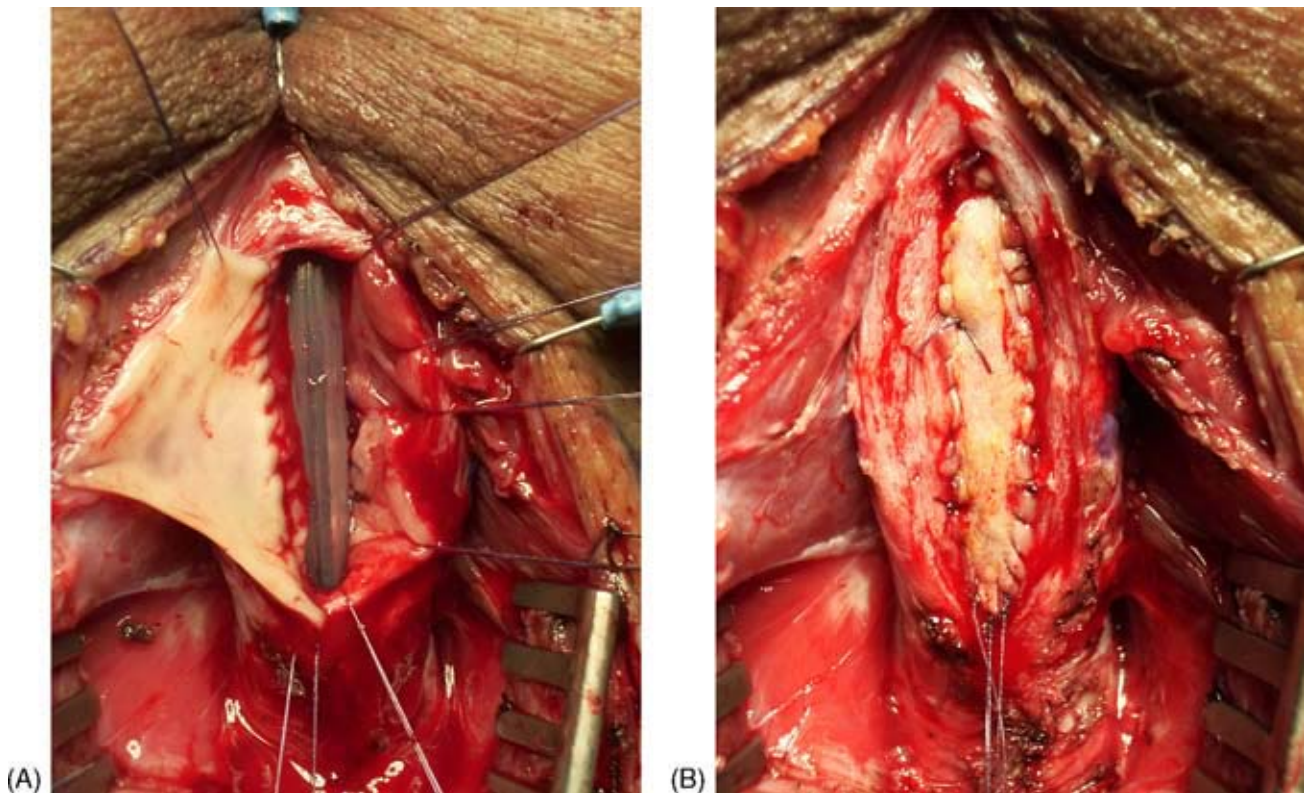
lengthen the urethral gap, increasing the risk of complications. Therefore a group stated that only bulbar strictures <1 cm were amenable to anastomotic reconstruction due to concerns that tension or tethering may cause strictures or erectile problems [2,13]. To reduce the risk of urethral chordee, graft-augmented anastomotic procedures have been advocated, but even with these techniques the problem of vascular damage after the complete urethral transection is still present.

Conversely, when compared with BMG patch techniques, the anastomotic procedures showed a higher incidence of penile curvature (36% vs. 8%), penile shortening (38% vs. 11%), impaired erection (79% vs. 15%), and impaired sexual life (57% vs. 19%). The overall satisfaction about sexual life was 97% in patients who underwent to BMG repairs versus 74% of those having anastomotic repairs [14]. In a series of 200 patients, Mundy reported temporary impotence in 53% who underwent anastomosis and 33% who underwent patch repair [15]. Coursey et al showed that anastomosis resulted in an overall dissatisfaction in erection and an alteration in erectile angle higher than BMG urethroplasty

(respectively, 26% vs. 19% and 44% vs. 38%) [16]. After anastomotic procedures on 22 patients, Morey and Kizer reported chordee (44.4%), decreased penile length (range: 22.2–33.3%), and overall satisfaction on erectile function only in 55.6%; particularly they reported complete loss of erection in two patients (9%) [12].

We were impressed to find that anastomotic urethroplasties were associated with so high a rate of erectile complaints. Factors impairing sexual life have an important impact on patient satisfaction and these problems may be as socially restricting as urethral stricture and may be more important than stricture recurrence. Success outcome in urethral repair should be assessed not only by objective voiding parameters but also by subjective parameters influencing satisfaction and these latter must be considered in the treatment choice.

However, in some traumatic strictures because of the hard scarring the urethral plate may be not preservable and amenable for the enlargement, requiring its resection by an anastomotic procedure. Thereby, the choice of the technique is always determined by the quality of the urethral plate.



**Fig. 5 – Ventral onlay patch augmentation. (A) The second buccal mucosa graft is sutured laterally to the mucosal margin of the urethral plate. (B) The graft is rotated and sutured to the other mucosal margin.**

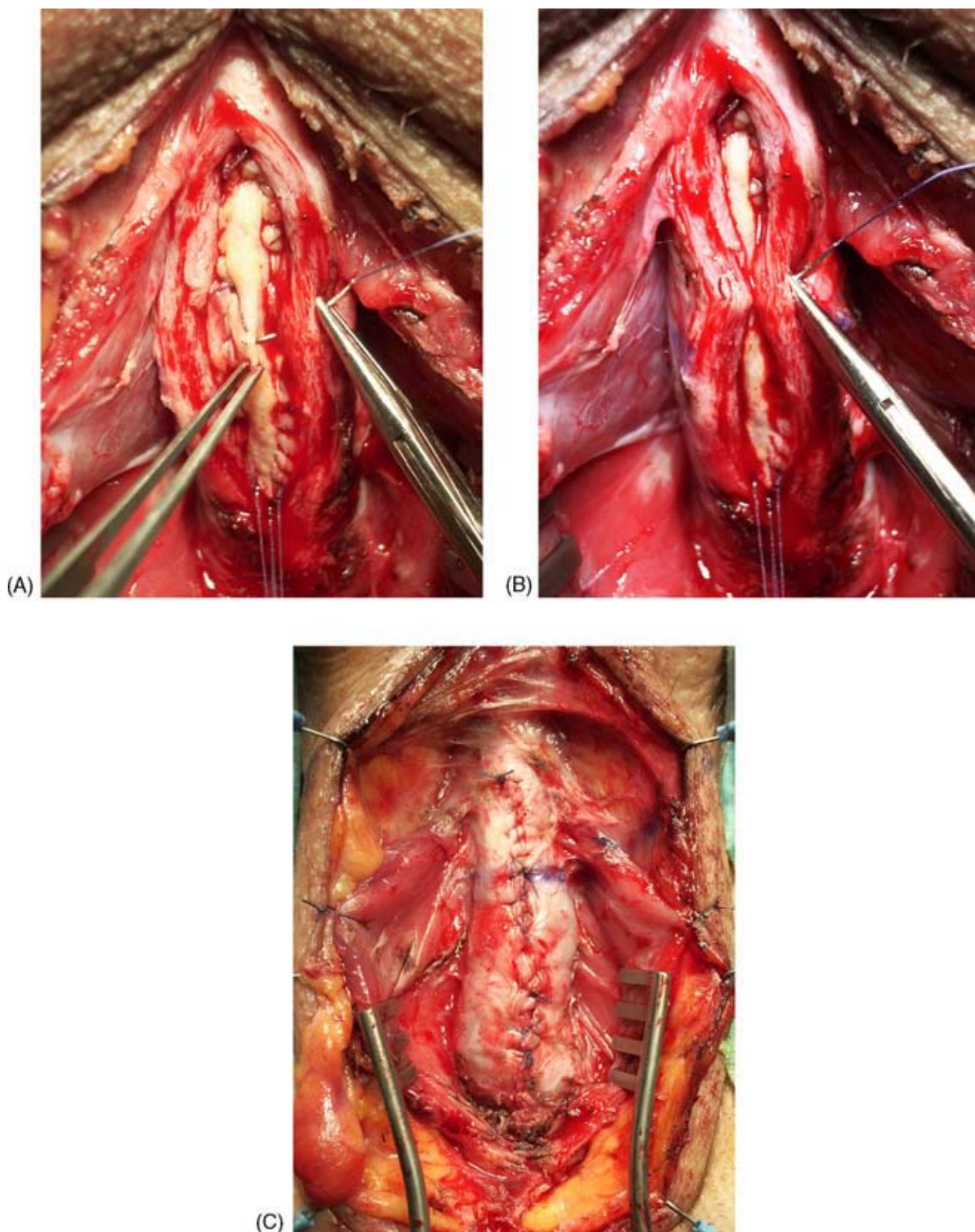
Most urologists commonly perform graft urethroplasty for strictures  $>2$  cm. Buccal mucosa represents the first choice of graft in the bulbar patch urethroplasty and many series shift from a ventral to a dorsal technique [3,6–10,17]. The dorsal graft placement can be performed by the Barbagli approach or the Asopa approach. The first consists in dissecting the urethra from the corpora cavernosa and its rotation of  $180^\circ$ ; the exposed dorsal urethral surface is opened and augmented with the graft splayed on the corpora. In case of previous repeated dilations or internal urethrotomies, the urethral detachment from the corpora may result in difficulty due to the fibrotic adhesions; furthermore, this approach may damage erectile function and the bulbar arteries when the dissection from the corpora needs to be very proximal [10,18].

In the Asopa procedure the urethra is approached by a ventral-sagittal opening; subsequently, the dorsal urethra is medially incised to create an elliptical area over the corpora where the graft is placed. This approach is easy to perform because the scarred urethra with marked spongiofibrosis is not mobilized; there is less harm for the urethral plate because the space for grafting is created without

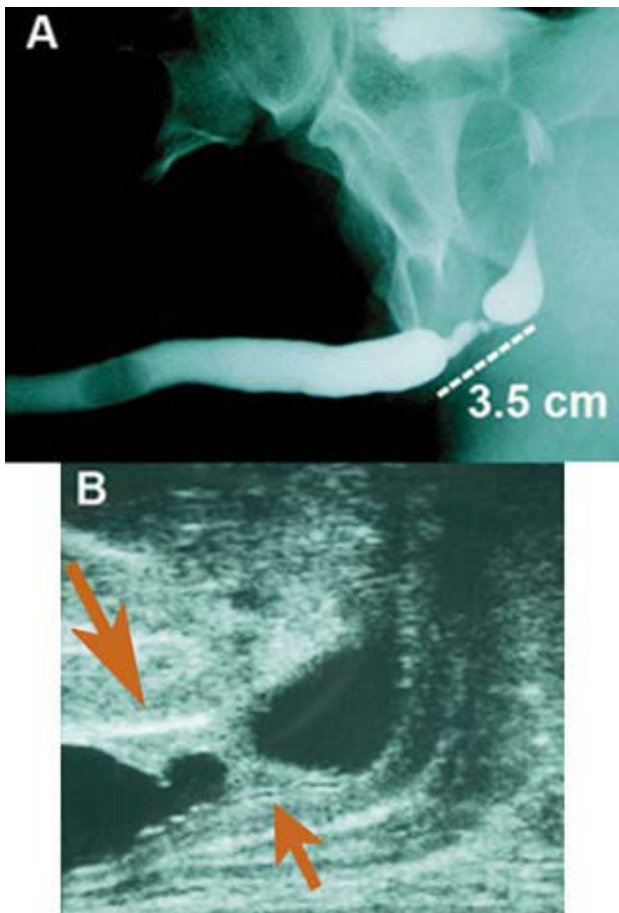
lifting the two urethral halves from the corpora and thereby the blood supply is guaranteed by the saved circumflex and perforating arteries [11]. The only technical limit of this method is that it seems to create a dorsal urethral enlargement less wide than with the Barbagli procedure.

In the ventral graft placement by McAninch, after a ventral-sagittal urethral opening the graft is anastomosed to the margins of the preserved dorsal urethral plate. In the presence of a urethral plate very tight or compromised from stenotic rings, the standard ventral augmentation could be inadequate. For these patients McAninch has suggested harvesting a 20-mm wide graft and in cases of near or complete obliteration of the urethra he used a 25-mm wide graft [3].

By adopting a combined dorsal and ventral double enlargement of very narrow strictured tracts, we aimed to create neo-urethras sufficiently wide and more stable, reducing the risk of recurrence at the distal or proximal graft anastomotic sites [10,19]. Compared with different series of single graft urethroplasties, the double patch enlargement does not show a decrease in the failure rate, but for tight strictures, it may avoid the more aggressive anasto-

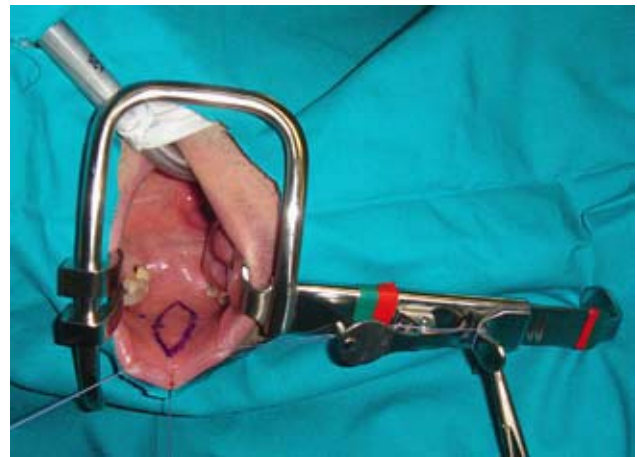


**Fig. 6 - (A and B) The inverted ventral graft is quilted by few stitches fixing the graft to the spongiosum. (C) Spongiosum closure over the graft.**



**Fig. 7 – (A) Tight bulbar stricture at the retrograde urethrography. (B) Dorsal and ventral spongiofibrosis clearly demonstrated on ultrasonography.**

motomic procedures with complete urethral transection that may compromise the spongiosum vascularity. Avoiding the transversal complete section of the spongiosum occurring in the anastomotic urethroplasties with or without added graft, we stick to the important concept of the urethral plate and preservation of its vascularity [20]. We also retained the original length of the urethral tube. Our aim was to maintain as much as possible the urethral axial integrity and to reduce the sexual complications related to an end-to-end urethroplasty, such as the chordee and the unpleasant feeling of loss of glans sensation. Even in our own experience with patients who underwent anastomotic procedures we have noticed temporary loss of glans sensation perhaps related to vascular involvement of the spongiosum distally to the urethral section. Usually the dorsal or ventral single graft urethroplasty is performed without resection of any diseased tissues, whereas the double graft enlargement allows the partial removal of the fibrotic urethral tissues without jeopardizing the creation of



**Fig. 8 – The Kilner-Doughty oral retractor.**

a wide enough lumen. Furthermore, the dorsal incision aims to release the scarred rings on the urethral plate.

The dorsal graft receives its vascular support by the corpora and the ventral graft is supported by the abundant ventral spongiosum. Only in the bulbar urethra is the ventral spongiosum hearty enough to provide vascularization adequate for graft viability and good mechanical support, preventing any sacculations or fistulas [3]. The inverted ventral graft-spongiosum quilting helps the graft survival. Furthermore, reducing the width of the ventral graft, the double graft technique may decrease the chance of fistulas and diverticulum.

In the past, full circumferential urethral reconstruction by one-stage graft tubes have demonstrated a high rate of complications due to diverticulum or restriction at the anastomotic sites. In contrast, the double patch technique with the inclusion of the residual lateral strips of the urethral plate allows a safer and more stable reconstruction, avoiding a circumferential anastomosis and preserving the axial continuity of the lumen.

Similarly to McAninch, we have successfully managed the recurrences by the internal urethrotomy; indeed, the well-vascularized grafted area usually develops a short and soft stricture, which responds better to incision than primary strictures surrounded by abundant scar tissue.

Because graft failure significantly contributes to the deterioration of the final outcome of the bulbar urethroplasties, further long-term trials are necessary to clarify the technical limits of any procedure and the true etiology of the strictures or other postoperative symptoms such as postvoiding dribbling and semen sequestration [10,18]. In our series, three patients referred semen sequestration but

without evidence of urethral sacculation. Yucel and Baskin supposed that the hypothetical damage during bulbar urethroplasty to the branches of the perineal nerves innervating the bulbospongiosus muscles may explain the loss of bulbar urethral contraction, causing difficulty in expelling semen and urine [21]. However, other factors may also have a role in the decrease of bulbar urethral contractions, such as the section of the perineal central tendon in the proximal bulbar strictures; finally, also spongiofibrosis disease and the ventral-sagittal urethrotomy, causing an interruption of the structural circularity of the muscle elastic urethral tube, may stop the voiding rhythmic urethral contractions.

Surely the best technique is the one with which the surgeon is most comfortable, but no single technique is appropriate in all situations and the successful reconstructive surgeon needs to have a repertoire of methods from which to choose.

## 5. Conclusions

Bulbar urethroplasties are today generally performed with preservation of the urethral plate and using the BMG ventrally or dorsally placed. We have combined these concepts to reduce the risk of recurrence in tight stricture repairs in which a narrow and inelastic urethral plate may require a more substantial augmentation. Longer follow-up and comparisons of series of bulbar repairs are necessary to clarify if the outcomes are related to the specific graft placement and to the use of a single or double patch augmentation.

## Conflicts of interest

The authors have nothing to disclose.

## Appendix A. Supplementary data

Supplementary data associated with this article can be found, in the online version, at [doi:10.1016/j.eururo.2007.05.033](https://doi.org/10.1016/j.eururo.2007.05.033) and via [www.europeanurology.com](http://www.europeanurology.com). Subscribers to the printed journal will find the supplementary data attached (DVD).

## References

- [1] Santucci RA, Mario LA, McAninch JW. Anastomotic urethroplasty for bulbar urethral stricture: analysis of 168 patients. *J Urol* 2002;167:1715–9.
- [2] Guralnick ML, Webster GD. The augmented anastomotic urethroplasty: indications and outcome in 29 patients. *J Urol* 2001;165:1496–501.
- [3] Elliott SP, Metro MJ, McAninch JW. Long-term followup of the ventrally placed buccal mucosa onlay graft in bulbar urethral reconstruction. *J Urol* 2003;169:1754–7.
- [4] Wessels H, McAninch JW. Use of free grafts in urethral stricture reconstruction. *J Urol* 1996;155:1912–5.
- [5] Baskin LS, Duckett JW. Buccal mucosa grafts in hypospadias surgery. *Br J Urol* 1995;76(Suppl):23–6.
- [6] Barbagli G, Palminteri E, Rizzo M. Dorsal onlay graft urethroplasty using penile skin or buccal mucosa in adult bulbourethral strictures. *J Urol* 1998;160:1307–9.
- [7] Pansadoro V, Emiliozzi P, Gaffi M, Scarpone P. Buccal mucosa urethroplasty for the treatment of bulbar urethral strictures. *J Urol* 1999;161:1501–3.
- [8] Morey AF, McAninch JW. When and how to use buccal mucosal grafts in adult bulbar urethroplasty. *Urology* 1996;48:194–8.
- [9] Kane CJ, Tarman GJ, Summerton DJ, et al. Multi-institutional experience with buccal mucosa onlay urethroplasty for bulbar urethral reconstruction. *J Urol* 2002;167:1314–7.
- [10] Barbagli G, Palminteri E, Guazzoni G, et al. Bulbar urethroplasty using buccal mucosa grafts placed on the ventral, dorsal or lateral surface of the urethra: are results affected by the surgical technique? *J Urol* 2005;174:955–8.
- [11] Asopa HS, Garg M, Singhal GG, Singh L, Asopa J, Nischal A. Dorsal free graft urethroplasty for urethral stricture by ventral sagittal urethrotomy approach. *Urology* 2001;58:657–9.
- [12] Morey AF, Kizer WS. Proximal bulbar urethroplasty via extended anastomotic approach—what are the limits? *J Urol* 2006;175:2145–9.
- [13] Webster GD, Koefoot RB, Sihelnik SA. Urethroplasty management in 100 cases of urethral strictures: a rationale for procedure selection. *J Urol* 1985;134:892–8.
- [14] Kessler T, Fish M, Heitz M, Olianias R, Schreiter F. Patient satisfaction with the outcome of surgery for urethral strictures. *J Urol* 2002;167:2507–11.
- [15] Mundy AR. Results and complications of urethroplasty and its future. *Br J Urol* 1993;71:322–5.
- [16] Coursey JW, Morey AF, McAninch JW, et al. Erectile function after anterior urethroplasty. *J Urol* 2001;166:2273–6.
- [17] Raber M, Naspro R, Scapaticci E, et al. Dorsal onlay graft urethroplasty using penile skin or buccal mucosa for repair of bulbar urethral stricture: results of a prospective single center study. *Eur Urol* 2005;48:1013–7.
- [18] Iselin CE, Webster GD. Dorsal onlay graft urethroplasty for repair of bulbar urethral stricture. *J Urol* 1999;161:815–8.
- [19] Palminteri E, Berdondini E, Colombo F, Austoni E. Small intestinal submucosa (SIS) graft urethroplasty: short-term results. *Eur Urol* 2007;51:1695–701.
- [20] Manzoni G, Bracka A, Palminteri E, Marrocco G. Hypospadias surgery: when, what and by whom? *BJU Int* 2004;94:1188–95.
- [21] Yucel S, Baskin LS. Neuroanatomy of the male urethra and perineum. *BJU Int* 2003;92:624–7.

### Editorial Comment on: Combined Dorsal plus Ventral Double Buccal Mucosa Graft in Bulbar Urethral Reconstruction

André Cavalcanti

Hospital Municipal Souza Aguiar, Rio de Janeiro, Brasil  
andre70211@hotmail.com

The use of a buccal mucosa graft is the first choice in bulbar urethral reconstruction. The success rate using buccal mucosa in the bulbar urethra is excellent, despite the graft position [1].

When we are performing any type of substitution, urethroplasty is necessary to observe the quality of the urethral plate after the urethrotomy. A narrow urethral plate is associated with difficulty in adjusting the graft or flap during the suture, especially in some cases such as traumatic strictures. In my personal opinion, an acceptable urethral plate width must be at least 0.5 cm and preferably close to 1.0 cm. When we are working with a urethral width <0.5 cm, we usually increase the graft or flap width, which can increase the risk of diverticular formation [2]. Barbagli et al. [3] described a failure rate of 20% after graft bulbar urethroplasty and observed that these failures usually occur at proximal and distal graft anastomotic sites.

The graft-augmented anastomotic urethroplasty [4] has been proposed as an option to increase the results of graft urethroplasty. This technique basically materializes the improvement in the urethral plate quality with the resection of the worst fibrotic area and an “anastomotic” reconstruction before the graft placement. But, as in any anastomotic urethroplasty, the graft-augmented technique has limits regarding the length of the stricture.

Palminteri and colleagues [5] first described the use of a combined ventral and dorsal graft in the bulbar urethra reconstruction. The authors observed an excellent success rate of 89.6% in a short-term follow-up. This new approach introduces new concepts about the importance of the urethral plate quality and its preservation during bulbar urethroplasty to treat tight and long strictures. A long-term follow-up is necessary to observe the possible advantages of this new technique against the standard simple graft urethroplasty.

### References

- [1] Barbagli G, Palminteri E, Guazzoni G, Montorsi F, Turini D, Lazzeri M. Bulbar urethroplasty using buccal mucosa grafts placed on ventral, dorsal or lateral surface of the urethra: are results affected by the surgical technique? *J Urol* 2005;174:955–8.
- [2] Elliott SP, Metro MJ, McAninch JW. Long-term follow-up of the ventrally placed buccal mucosa onlay graft in bulbar urethral reconstruction. *J Urol* 2003;169:1754–7.
- [3] Barbagli G, Guazzoni G, Palminteri E, Lazzeri M. Anastomotic fibrous ring as cause of stricture recurrence after bulbar onlay graft urethroplasty. *J Urol* 2006;176:614–9.
- [4] Guralnick ML, Webster GD. The augmented anastomotic urethroplasty: indications and outcome in 29 patients. *J Urol* 2001;165:1496–501.
- [5] Palminteri E, Manzoni G, Berdondini E, et al. Combined dorsal plus ventral double buccal mucosa graft in bulbar urethral reconstruction. *Eur Urol* 2008;53:81–90.

DOI: [10.1016/j.eururo.2007.05.034](https://doi.org/10.1016/j.eururo.2007.05.034)

DOI of original article: [10.1016/j.eururo.2007.05.033](https://doi.org/10.1016/j.eururo.2007.05.033)